

# Subcision Plus Sublative Technologies to Treat Acne Scars

Combining something old and something new to create something skintastic.

BY JORDAN HARDESTY AND SANDRA MARCHESE JOHNSON MD, FAAD

Severe acne on the face, chest, and back can cause permanent changes in the skin that we refer to as acne scarring.<sup>1</sup> When follicular pores become congested with bacteria, oil, and/or dead skin, inflammation, and follicular rupture result. Even though the body attempts to repair this damage, that repair is not perfect and there is often ensuing scarring.<sup>2</sup> Acne scars commonly vary in pigment color and skin thickness. Atrophic or depressed scars are most commonly found on the face and result from insufficient collagen production during the repair process. Hypertrophic or raised scars are most commonly found on the chest and back and result from the overproduction of collagen.<sup>2</sup> Several factors contribute to the formation of acne scars. Those who suffer or postpone treatment of inflammatory acne are at risk for scarring. This risk is also increased by genetic factors as well as endogenous factors that raise the level of inflammation in the skin.<sup>3</sup>

Many believe that prevention is the best way to guard against formation of acne scars; however, for many people acne is unavoidable.<sup>3</sup> There are several treatment options to help improve the condition of acne scars. For this article, we will be focusing on depressed acne scars. Some treatments for atrophic scars include topical retinoids, injection of fillers, ablative and non-ablative laser treatments, TCA chemical peels, radiofrequency treatments, vascular lasers, needling, dermabrasion, and surgical methods. These surgical methods include punch elevation, punch excision, and subcision.<sup>1</sup>

## CASE REPORT

We report a case of a teenage female patient who suffered with scarring acne and was treated with conventional medical therapies. The patient had suffered from acne for

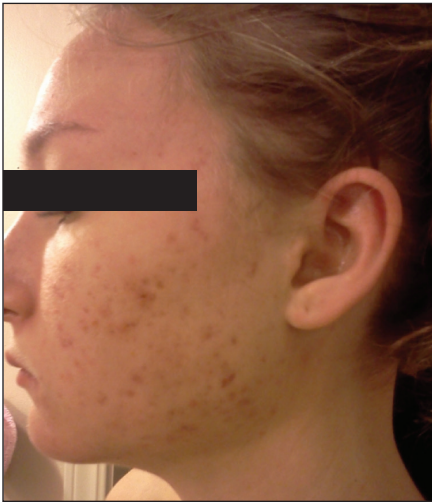“Subcision is a minor surgical procedure that has been used in dermatology for decades. It has become somewhat of a lost art.”

over seven years and was treated with several oral therapies, topical medications, and chemical peels. The patient and her mother wanted to improve her acne scarring, but her rigorous athletic schedule precluded more aggressive treatments or untoward downtime. Originally, the patient was treated with the recommended three treatments of sublative radiofrequency, but desired better results. She was treated with three sessions of subcision and sublative with good results. Upon follow-up, the patient reported an increase in her self-confidence and self-esteem. Her photographic progression is presented in Figures 1-3.

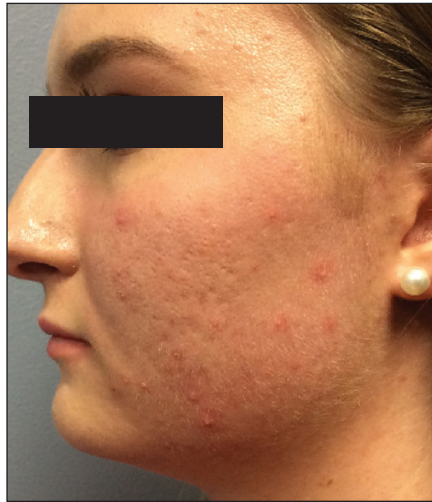## DISCUSSION

Subcision is a minor surgical procedure that has been used in dermatology for decades. It has become somewhat of a lost art. With the addition of Cellfina (Merz Aesthetics), there has been renewed interest in subcision, with or without the use of the device, which helps to facilitate the procedure.

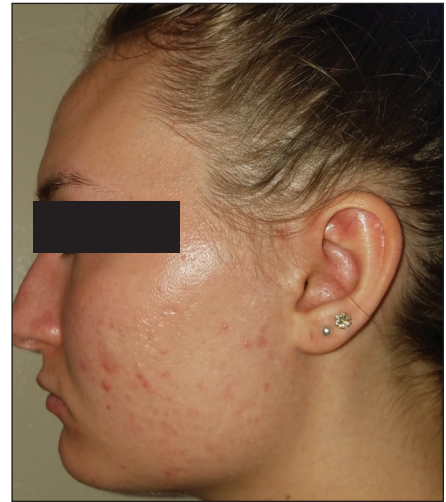
Subcision helps to improve the appearance of wrinkles, cellulite, and acne scars. The procedure is often performed with local anesthesia and a hypodermic needle. Some people prefer a Nokor needle for subcision.



**Figure 1:** Initial presentation in 2011. Note the red, brown, and flesh toned atrophic, indented/inverted papules consistent with acne scarring.



**Figure 2:** Six years later, note the active acne as well as acne scarring before subcision and sublative treatments.



**Figure 3:** Post-treatment. Note the improved skin tone and texture after three subcision and sublative treatments. Patient still has active acne, however scarring is much improved.

The technique involves obtaining consent and thoroughly cleansing and prepping the skin. Tumescent lidocaine is performed, then the needle is inserted parallel to the surface of the skin into fibrotic scarred tissue, which is often in the deep dermis. The needle is then moved under the skin to break the fibrous bands that anchor the scar tissue to the healthy subcutaneous tissue. A fan-like motion with the needle helps to reach more of the anchored tissue, causing it to release, decreasing the depth of the scar. Different puncture sites are created for individual scars to produce the best results.<sup>4</sup>

Another treatment that proves effective in the improvement of acne scarring is radiofrequency treatment. Sublative resurfacing sends radio waves through electrodes, heating up the dermis of the targeted area of the skin, while relatively sparing the epidermis. When the dermis is heated, it promotes the production of collagen and skin tightening.<sup>5</sup> Sublative resurfacing is well tolerated and is reportedly the only technology proven to reduce moderate to severe acne scars for all skin types. The eMatrix (Candela) sublative RF applicator is designed to deliver radiofrequency energy to the skin in a fractional manner, via an array of multi-electrode pins. The array delivers bipolar RF energy to the skin. Microscopic zones of epidermis and dermis are thermally ablated in a grid over the skin surface, where non-ablated zones serve as a reservoir of cells that promote rapid healing. Figure 4 demonstrates how traditional fractional ablative resurfacing affects more of the epidermis with potentially more downtime, whereas sublative rejuvenation has the reverse effect, with more

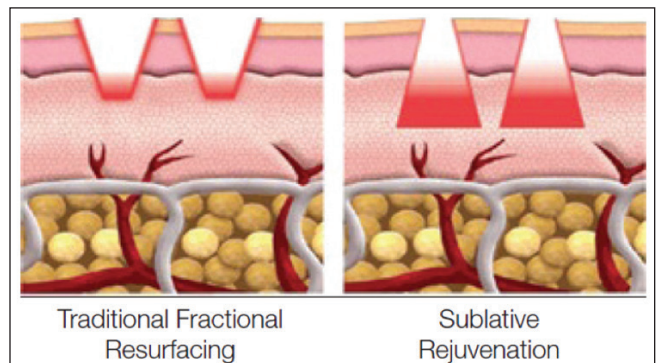


Photo courtesy of Candela.

**Figure 4:** Traditional fractional resurfacing has larger cones of treatment to the epidermis and less penetration into the deeper dermis. The reverse is true for sublative rejuvenation.

energy delivered to the dermis not the epidermis.<sup>6</sup>

Side effects of sublative therapy include mild discomfort and temporary erythema of the treated area. This treatment has little to no downtime, and the patient can expect to see results over time as the collagen is remodeled. Again, according to Candela, because it is radiofrequency and not laser or light based, it is safe for all Fitzpatrick skin types.<sup>6</sup> For best results, it is recommended to have this treatment done monthly for three months.

Subcision and sublative are individually both successful in improving the appearance of acne scarring. We propose in this paper a novel and successful treatment that combines these two treatments in order for the patient

*(Continued on page 66)*

(Continued from page 48)

“Subcision and sublative are individually both successful in improving the appearance of acne scarring.

We propose in this paper a novel and successful treatment that combines these two treatments...”

to receive increased synergistic benefit. If the scar tissue is still tethered to the subcutaneous tissue, collagen stimulation from radiofrequency is diminished. When combining subcision and sublative treatment, the dermis is altered in such a way as to create tissue that is more responsive to collagen stimulation resulting from radiofrequency energy facilitated by sublative resurfacing.

### COMBINATION FOR INCREASED SATISFACTION

It has been our experience that combining the two treatments has increased patient satisfaction. After identifying that a patient is a good candidate for these combined treatments and consenting or assenting the patient, we perform the subcision procedure. Sublative radiofrequency follows the subcision to the entire treatment area directly afterward. The patient may experience mild bruising, edema, and discomfort during the first few days of recovery. Before and after pictures are taken of the treated area. We advise the patient not to use any topical products or expose the treated area to water or cold compresses until the following day. Care after this time period includes cold compresses, sun avoidance, and application of white petrolatum as needed. ■

*Sandra Marchese Johnson, MD, FAAD is a provider at Johnson Dermatology in Fort Smith, AR and a past president of the Arkansas Dermatologic Society.*

*Jordan Hardesty is a second year (sophomore) student at Hendrix College who plans to pursue a career in medicine. She is the patient presented in this paper who was so happy with the outcome that she wanted to share her experience with others.*



1. Lim, D. Acne Scars (Acne Scarring). The Australian College of Dermatologist. Retrieved from <https://www.dermcoll.edu.au/atoz/acne-scars-acne-scarring-2/>. Accessed April 25, 2018.
2. Acne Scars. American Society for Dermatological Surgery. Retrieved from <https://www.asds.net/Acne-Scars/>. Accessed April 25, 2018.
3. Acne Scars. American Academy of Dermatology. Retrieved from <https://www.aad.org/public/diseases/acne-and-rosacea/acne-scars#overview>. Accessed April 25, 2018.
4. Chandrashekar, B., Nandini, A. Acne Scar Subcision. *Journal of Cutaneous and Aesthetic Surgery*. 2010;3(2):125-126. doi:10.4103/0974-2077.69029.
5. Sublative Fractional Resurfacing Effective for Treating Signs of Photoaging. *Dermatology Times*. 2011. Retrieved from <http://www.dermatologytimes.com/modern-medicine-now/sublative-fractional-resurfacing-effective-treating-signs-photoaging>. Accessed April 25, 2018.
6. Sublative RF Technology (2016). Syneron Candela. Retrieved from <https://syneron-candela.com/int/technology/sublative-rf-technology>. Accessed April 25, 2018.